International Journal of Dermatology, Vol. 34, No. 7, July 1995

REPORT

PHOTODAMAGE AND SKIN CANCER AMONG PARAQUAT WORKERS

SHIOU-HWA JEE, M.D., PH.D.,

HSIEN-WEN KUO, M.P.H., W.P. DANIEL SU, M.D.,

CHUN-HSIANG CHANG, M.D., CHEE-CHING SUN, M.D., AND JUNG-DER WANG, M.D., D.SC.

Abstract

Background. Some workers in paraquat manufacturing, exposed to bipyridines, have developed pigmentation and keratosis on sun-exposed skin. This condition has been described as skin-malignancy or premalignancy. This study was designed to clarify the pathologic features of these lesions and to explore the etiologic role played by bipyridine.

Methods. Twenty-three biopsy specimens, obtained from the affected skin of 10 workers, were scrutinized by a dermatopathologist. A total of 242 exposed workers from 28 paraquat factories were examined and interviewed during the period from 1983 to 1991. The severity of the characteristic skin lesions was graded from the lowest to the highest response to analyze the data by Mantel extension for a trend that focused on the heavy exposure to bipyridines as risk factor.

Results. All pathology specimens showed various degrees of solar damage: early actinic change, solar lentigo, actinic keratosis (AK), AK coexisting with squamous cell carcinoma (SCC), and SCC. Six specimens from four workers were SCC or SCC in situ. Three of six SCC showed the coexistence of AK. Of the workers, 133 had skin lesions ranging in severity from grade 1 to grade 3 on sun-exposed areas. The severity of skin changes is strongly associated with heavy exposure to bipyridines ($P < 0.0001$).

Conclusion. This pathologic study proves that all the lesions showed either photodamage or skin cancer. The strong trend in the correlation between severity of photodamage and exposure to bipyridine leads to the speculation about the synergistic role of bipyridine exposure and the solar effect in causing these malignant and premalignant skin lesions.

Int J Dermatol 1995; 34:466–469

Paraquat has been a widely used herbicide in the agricultural industry of Taiwan. Bipyridine, a precursor of paraquat, is toxic to humans. In 1982, Bowra et al.[1] reported squamous cell carcinoma (SCC) and Bowen's disease occurring in workers exposed during the manufacture of bipyridine. They believed a "tarry" by-product was the causative agent. Since that year, paraquat workers have been observed to develop hyperpigmentation and reddish, scaly papules on face, neck, arms, hands, and legs (Fig. 1). The extensor surfaces of the forearms were affected more than the flexor surfaces (Fig. 1). In an epidemiologic analysis of 28 paraquat manufacturers in Taiwan in 1985, the skin lesion was described as a premalignancy associated with exposure to bipyridines and/or its isomers.[2] The present study found pathologic evidence of photodamage and oncogenic change of the skin among 11 selected workers with representative skin manifestations. After grading the severity of skin lesions among 242 paraquat factory workers, it was possible to demonstrate the strong association with heavy exposure to bipyridines.



Figure 1. Characteristic skin lesions of paraquat workers. *A*, Hyperpigmented and keratotic lesions distributed mainly on face, neck, and arms. *B*, Extensor aspect of arms is more severely affected than the flexor aspect.

From the Department of Dermatology, and the Institute of Public Health, Center for Research of Environmental and Occupational Disease, College of Medicine, National Taiwan University Hospital, Taipei, Taiwan; and the Department of Dermatology, Mayo Clinic, Rochester, Minnesota.

Supported by the National Science Council of the Republic of China (NSC-81-0412-B006-637) and the Department of Health, the Executive Yuan, Republic of China (DOH-81-44).

Address for correspondence: Shiou-Hwa Jee, M.D., Ph.D., Department of Dermatology, National Taiwan University Hospital, Taipei, Taiwan, 100.



Figure 2. Grading of photodamage. Photographed from extensor aspect of forearms in a 3 × 6 cm rectangle. *A*, Grade 1: tiny freckles or scattered lentigines on skin. *B*, Grade 2: confluent solar lentigenes and few actinic keratoses. C, Grade 3: heavy hyperpigmentation and multiple keratosis.

Materials and Methods

Histopathologic Study: Biopsies were taken of skin lesions from 11 selected workers considered to be representative of the affected workers; there were 23 pathologic specimens for evaluation.

Epidemiologic Analysis: A total of 242 workers in 28 paraquat factories were examined. Photographs for all suspicious lesiosn were taken for later objective evaluation. Two photographs, 3 x 6 cm, were taken from the extensor aspects of the forearms with 156 pairs of photographs taken in all. The remaining 86 workers had no apparent skin lesions. Based on these photographic records, the severity of the lesions was graded as follows: (1) grade 1: multiple tiny freckles or scattered lentigines within a rectangular area; (2) grade 2: confluent solar lentigines and a few actinic keratosis lesions; and (3) grade 3: heavy hyperpigmentation and multiple actinic keratoses or possibly malignancy (Fig. 2). The severity grades of the skin lesions were used as an endpoint for epidemiologic analysis.

There were 28 paraquat factories operating in Taiwan during 1983–1984. The process of paraquat manufacturing in those factories was reviewed. A questionnaire was collected from each worker. Its content included risk factors for skin cancer (e.g., histories of irradiation, intake of inorganic arsenic, and previous history of skin cancer). About two-thirds of the factories produced paraquat from bipyridines after centrifugation and crystallization in an open area (Fig. 3); a worker was defined as "heavily exposed" if that was his or her particular work. The Mantel extension for the trend[3] was used to analyze the in-trend association by severity-grading of lesions from heavy exposure to bipyridines.

RESULTS

Histopathologic Study

As shown in Table 1, all affected workers had various degrees of photodamage. Except for worker number 11, all 10 workers who underwent skin biopsy had actinic keratosis (AK). Four persons developed squamous cell carcinoma (SCC) or in situ SCC at ages 37–53 years, and after exposure of bipyridine from 6 to 14 months. Of the lesions per se, three were solar lentigo, 11 were AK, 3 were SCC in situ coexiting with AK, and 3 were SCC (Fig. 4).

Epidemiologic Data and Statistical Analysis

None of the affected workers had a history of previous irradiation, exposure to arsenic, or of skin cancer.

One hundred and thirty-eight paraquat workers developed skin lesions. Five workers with large blotchy hyperpigmented and mottled skin lesions did not fall into any one of the three grading categories. Among 133 patients with skin lesions from grades 1 to 3, there was a trend of association between heavy exposure and the severity of skin lesion (Mantel extension for the trend: $P < 0.0001$). Thirteen patients had severe grade 3 skin lesions, and the odds ratio of developing grades 0,

Figure 3. Open tanks containing "tarry" bipyridines in the work area where centrifugation and crystallization is done.

Table 1. Clinical and Pathologic Features of 11 Paraquat Workers

Factories	*Case No.*	*Age*	*Duration of Bipyridine Exposure (M)*	*Severity Grading*	*Clinical Lesions*	*Pathology*
A	1	53	11	3	Nodule	SCC in situ and AK
					Papule	AK
					Papule	AK
B	2	37	12	3	Papule	SCC in situ and AK
	3	44	14	3	Red papule	AK
	4	46	14	3	Red keratotic papule	AK
	5	44	13	3	A: red, scaly papule	SCC in situ and AK
					B: keratotic papule	AK
C	6a	37	6	3	Red scaly plaque	SCC
	6b	43	7	3	Cutaneous horn	SCC
					Star-like pigmentation	AK
					Pigmented keratotic papule	SCC
	7	32	3	2	Red keratotic papule	AK
					Light brown macule	Solar lentigo
	8	47	4	3	Star-like pigmentation	AK
					Pigmented scaly patch	Solar lentigo
					Keratotic papule	AK
D	9	54	5	1	Macule	AK
	10	31	5	1	Reddish keratotic papule	AK
	11	43	5	1	Macule	Solar lentigo
					Normal	Early actinic change
					Hypopigmentation	Early actinic change

AK = actinic keratosis; SCC = squamous cell carcinoma.
Actinic elastosis was present on all biopsy specimens except 6b.

1, 2 and 3 lesions were 1, 3.9, 3.2, and 85.7, respectively (Table 2).

DISCUSSION

The development of malignant and premalignant lesions of the skin among paraquat workers has been reported previously.[1,2] In this study, we report photodamage and photocarcinogenesis with strong in-trend association with exposure to bipyridines among paraquat manufacturers.

The diagnosis of photodamage and photocarcinogenesis is based on such characteristic skin manifestations in affected workers as pigmentation and AK-like reddish papules disseminated over sun-exposed areas

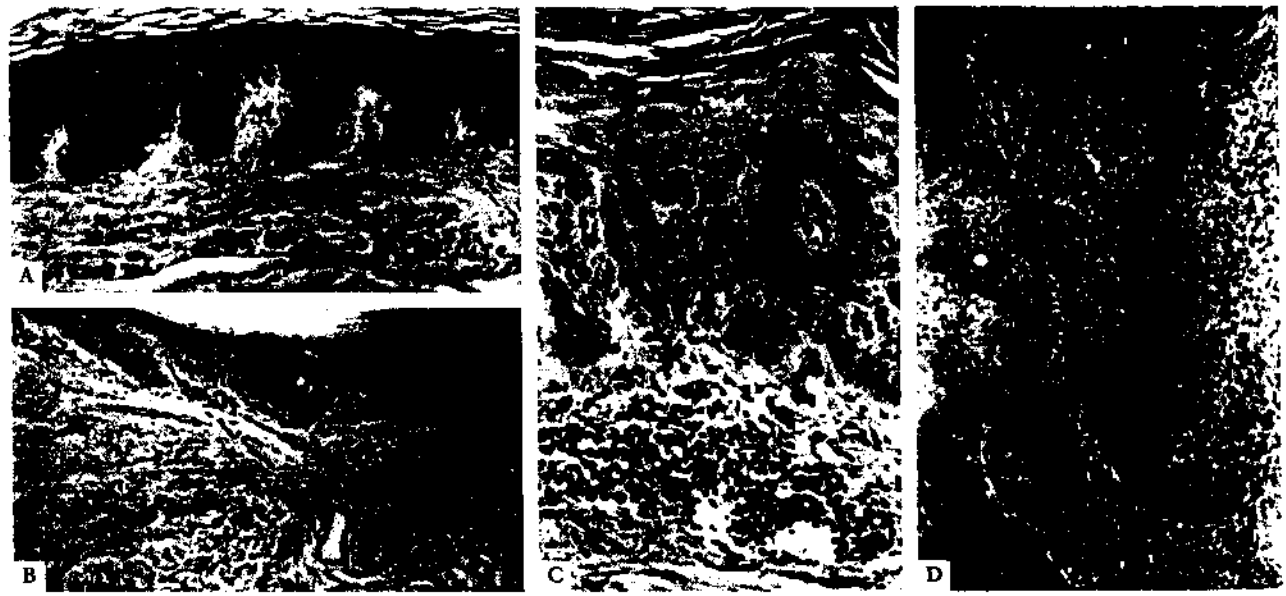

Figure 4. Pathologic changes in skin lesions of paraquat workers. *A*, Solar lentigo from a pigmented scaly patch. *B*, Actinic keratosis, common type, from a keratotic plaque. *C*, Squamous cell carcinoma coexisting with actinic keratosis from a reddish scaly papule. *D*, Squamous cell carcinoma from a blackish keratotic papule. (hematoxylin and eosin, magnification × 100)

Table 2. Relevance of Severity and Exposure to Bipyridines

	Grade			
Exposure	*0 (%)*	*1 (%)*	*2 (%)*	*3 (%)*
No	89 (85.6)	22 (62.9)	56 (65.7)	1 (7.7)
Yes	15 (14.4)	13 (37.1)	29 (34.1)	12 (92.3)
Odds ratio	1	3.9	3.2	85.7

Mantel extension for the trend: $\chi^2 = 30.1$, $P < 0.0001$.
Note: Five workers with blotchy pigmentation were not included in this grading.

where the extensor aspects of the forearms are much more affected than the flexor surfaces. Actinic elastosis is the histologic hallmark of photodamage;[4,5] all except one of the pathology specimens showed this hallmark with various degrees of photodamage, including mild dysplasia of keratinocytes, solar lentigo, AK, SCC with AK. Only SCC was present in all 23 specimens. Statistical analysis showed an obvious association between bipyridine exposure and the severity degree of photodamage.

The well-known photocarcinogens include psoralen used in photochemotherapy (PUVA) for psoriasis patients.[6,7] Psoralen interacts with both UVA and UVB. Other photocarcinogens reported include tar,[8] polycyclic hydrocarbons,[8,9] nitrosourea, and nitrogen mustard that has an additive carcinogenic effect in conjunction with UVB radiation.[10] Some chemicals such as croton oil, phorbol ester, and transretinoic acid can promote UVB-initiated carcinogenesis,[11] but each of the above photocarcinogens has a different mechanism and role in promoting photodamage and skin cancer. Since the absorption spectrum of 4,4'-bipyridine is UVC, which is not in the sunlight spectrum, this photodamage and photocarcinogenesis may not result from direct interaction of sunlight and bipyridine. The exact photocarcinogenesis of bipyridine needs further investigation.

REFERENCES

1. Bowra GT, Duffield DP, Osborn AJ, Purchase IFH. Premalignant and neoplastic skin lesions associated with occupational exposure to 'tarry' byproducts during manufacture of 4,4'-bipyridyl. Br J Ind Med 1982; 39: 76–81.
2. Wang JD, Li WM, Hu FC, Hu KH. Occupational risk and development of premalignant skin lesions among paraquat manufacturers. Br J Ind Med 1987; 44:196–200.
3. Mantel N. Chi-square tests with one degree of freedom: extension of Mantel-Haenszel procedure. J Am Statist Assoc 1963; 58:690–700.
4. Gilchrest BA. Skin aging and photoaging: an overview statistic. J Am Acad Dermatol 1989; 21:610–613.
5. Kligman AM. Solar elastosis in relation to pigmentation. In: Fitzpatrick TB, Pathak MA, Harber LC, et al., eds. Sunlight and man—normal and abnormal photobiological response. Tokyo: University of Tokyo Press, 1974:157.
6. Stern RS, Thibodeau LA, Kleinerman RA, et al. Risk of cutaneous carcinoma in patients treated with oral methoxsalen photochemotherapy for psoriasis. N Engl J Med 1979; 300:809–813.
7. Chuang TY, Heinrich LA, Schultz MD, et al. PUVA and skin cancer. J Am Acad Dermatol 1992; 26:173–177.
8. Stern RS, Zierier S, Parrish JA. Skin carcinoma in patients with psoriasis treated with topical tar and ultraviolet radiation. Lancet 1980; i:732–735.
9. Epstein SS, Small M, Falk HL, Mantel N. On the association between photodynamic and carcinogenic activities in polycyclic compounds. Cancer Res 1964; 24:855–862.
10. Santamaria L, Giordano GG. Effects of long-wave ultraviolet radiation on polycyclic hydrocarbon carcinogenesis. In: Urbach F, ed. The biologic effects of ultraviolet radiation. Oxford: Pergamon Press, 1969:569.
11. Epstein JH. Photocarcinogenesis, skin cancer and aging. J Am Acad Dermatol 1983; 9:487–502.

Proprietary topical agents, from the collection of Lawrence Charles Parish, M.D., Philadelphia, Pennsylvania.